

Case Report

Management of Long Standing TMJ Dislocation: Report of Three Cases

¹Neeraj Kumar Dhiman, ²Arun Pandey, ³Ajit Kumar Vishwakarma, ⁴Vishal Verma, ⁵Shankar Singh

Assistant Professor¹, Senior Resident^{2,4}, Junior Resident^{3,5}

Department of Oral and Maxillofacial Surgery, Faculty of Dental Sciences, Institute of Medical Sciences, Banaras Hindu University, Varanasi (India)

ABSTRACT:

Chronic long standing dislocation of the temporomandibular joint (TMJ) is a relatively rare occurrence. Variation in the duration of dislocation and anatomical considerations make the treatment for long-standing dislocation very complex. In this paper we present three cases of long standing TMJ dislocation and review of literature with treatment options for chronic TMJ dislocation.

Key words: Condyle dislocation, Hypermobility, Temporomandibular joint.

Received: 09 February 2018

Accepted: 18 February 2018

Corresponding Author: Dr. Neeraj Kumar Dhiman, Assistant Professor, Faculty of Dental sciences, Institute of Medical Sciences, Banaras Hindu University, Varanasi (India).

This article may be cited as: Dhiman NK, Pandey A, Vishwakarma AK, Verma V, Singh S. Management of Long Standing TMJ Dislocation: Report of Three Cases. J Adv Med Dent Scie Res 2018;6(2):55-58.

INTRODUCTION:

Temporomandibular joint (TMJ) dislocation typically occurs when the condyle becomes displaced out of the glenoid fossa and anterior to the articular eminence, although few reports also describe posterior, lateral, and superior dislocations. This can be unilateral or bilateral with most of the cases occurring bilaterally. Predisposing factors for condylar dislocation include yawning, trauma, dental treatments, & medications like anti-emetics metoclopramide and compazine which produce extra pyramidal effects and along with these systemic diseases such as Ehlers–Danlos and Marfan syndromes, congenital joint weakness, and psychogenic and neurological disorders ^[1, 2]. TMJ dislocation can be categorized into three groups: acute; habitual; and long-standing ^[3]. Acute dislocation is the most common and is defined as a sudden onset of the condyle being displaced anteriorly beyond the articular eminence, which cannot be reduced by the patient. This can be managed by manipulating the mandibular condyle downward and backward into the glenoid fossa with or without local anaesthesia or sedation. Habitual dislocation or chronic recurrent dislocation is relatively rare, and is defined as repeated episodes becoming more frequent and progressively worse ^[4]. Huang et al. suggest that chronic dislocation be defined as acute dislocation left untreated or

inadequately treated for 72 h or more ^[5]. Long-standing dislocation or protracted dislocation is rarer, and is defined as dislocation not reduced immediately ^[6]. Here we have case report of three post-trauma long standing TMJ dislocations.

CASE REPORT: 1

A well built 40 years old male patient reported to our centre with chief complains of inability to close mouth, difficulty in speaking and swallowing since last 2 months (Fig.1) following direct blow to the chin by tractor operated chaff cutter machine. He received treatment from several doctors near his locality but did not relieve from the problem. Due to long standing discomfort he developed persistent pain in fronto-perital, occipital and cervical regions. Patient has no previous history of TMJ dislocation, hypermobility syndrome or any injury to the joint.

Tenderness in bilateral pre-auricular region, hollow bilateral condylar fossa and anterior open bite were clinical findings leading to diagnosis of bilateral TMJ dislocation which was confirmed by computed tomography (Fig.2).

Initially Nilaton's technique of manual reduction was attempted under local anaesthesia but reduction cannot be achieved, then same procedure was repeated in the

emergency department using intravenous 5 mg midazolam and 5 mg diazepam; but again we failed to reduce the joint. Lastly surgical intervention under general anaesthesia was planned. Right Sub-mandibular incision was given to expose mandibular angle, a hole was drilled in the angle and a 24 gauge wire passed through it to pull the mandible downward but reduction was not achieved, further angle was osteotomized and ramus condyle unit was pulled downwards and backwards by same wire and also by bone holding forceps. But again we failed to achieve reduction. Finally right condylectomy was performed and open reduction of left condyle was done through alkayat and brahmely approach. Internal fixation of osteotomized angle was done with miniplates (Fig.3) and flaps were closed in layers.

CASE REPORT: 2

A 45 years old female patient was referred by local practitioner for the correction of her abnormal bite following trauma from rubber boll with the chief complain of pain and deviation of the jaw toward Right side since 1 month. According to her interpreter, the malocclusion had been present for 2 months and had made her unable to chew properly. There was mild tenderness on the left ramus and temporomandibular joint and significant pre-auricular depression was also noted. She was able to close his lips to form words and had minimal drooling, but the jaw is in cross bite on right side.

Two attempts of manual reduction were performed within the period of one week. In the first attempt, auriculo-temporal, masseteric and posterior deep temporal nerves were blocked and manual reduction was attempted but not worked. Due to failure and patient's discomfort, we decided to wait a week before making a new attempt. At this time, we applied the same type of extra-oral anesthesia associated with intravenous sedation, but again reduction was not achieved.

Finally under general anaesthesia manual reduction was again attempted by pulling the chin upward and using the bite block as fulcrum in left molar region but it did not worked.

At last a langenbeck retractor was inserted in the left mandibular notch through retro-mandibular approach and by downward pull of retractor along with Nilaton's technique of manual reduction condylar reduction was achieved.

CASE REPORT: 3

A 57 years old male patient reported with alleged history of trauma to the lower jaw 2 months back when he falls on hand water pump while using it, after that he noticed pain and swelling in chin region with difficulty in chewing and inability to close mouth. The patient neglected the trauma as impact was minimal and the swelling was subsided after 5 days, but the complain of difficulty in chewing and inability to close mouth remains persistant. He again neglected and

was on liquid diet for 2 months, during this period his neighbors advised him to consult dental surgeon.

At our center patient was advised to get an orthopantomogram (OPG) x-ray which shows bilateral dislocation of TMJ. Two attempts of manual reduction were performed under local anaesthesia along with traction but we failed to reduce the joint.

Further under general anaesthesia symphysis was osteotomized making two hemi-mandibles. Now manually each hemi-mandible was reduced followed by internal fixation of osteotomized symphysis.

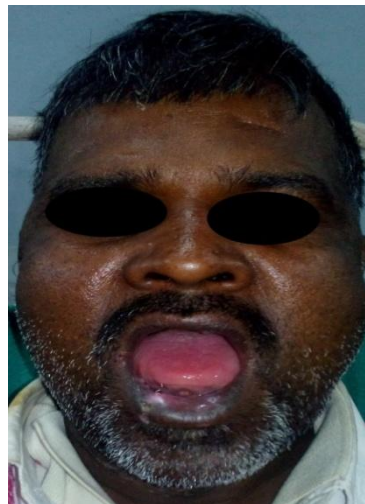

Fig.1: Clinical presentation of TMJ dislocation.

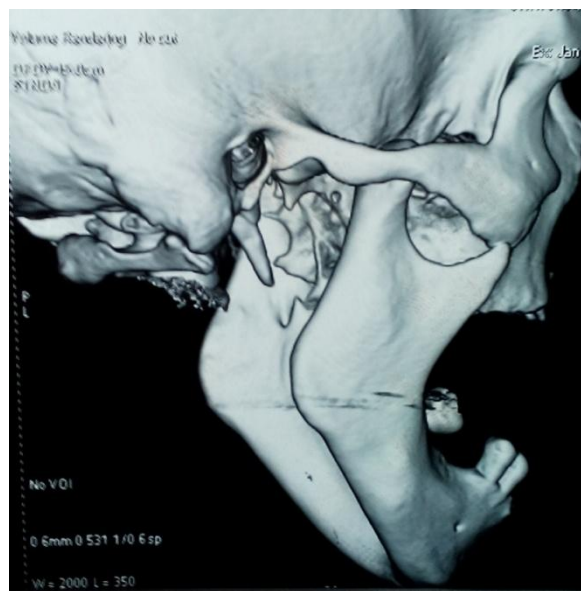


Fig.2: Computed tomography (CT) face showing dislocated condyle in infratemporal fossa.

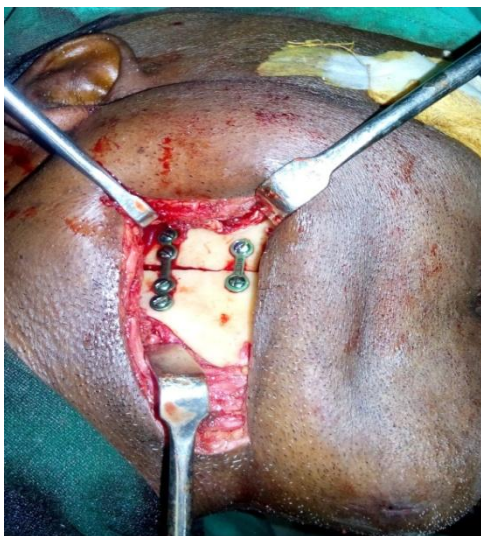


Fig.3: Osteotomised angle fixed with titanium miniplates.

DISCUSSION:

Chronic long-standing dislocation of TMJ is very rare. Gottlieb reported 24 cases of long-standing dislocation of the TMJ [7]. Wijmenga et al; presented three new cases of long-standing dislocation of the TMJ and reviewed 37 cases from 1952 to 1982[3]. Dislocation causes muscle spasm, fibrosis soft tissue and soft tissue in-growth into the glenoid fossa making reduction extremely difficult. There is no clear indication of significant period of time for reduction of a long-standing dislocation of the TMJ. However longer the dislocation, the more difficult the reduction of the condyle [8].

Huang et al; presented six cases of long standing TMJ dislocation. In their case series, they discovered that dislocations lasting for more than 30 days were extremely difficult to be managed by conventional manipulation even under general anaesthesia. They suggested that when long-standing dislocation has persisted for 4–12 weeks it is best treated by open reduction after stripping the periosteum of the ramus area as widely as possible and using conventional manipulation with the assistance of wire traction at the angle or insertion of a U shaped stripper into the sigmoid notch to pull the mandible downward. They also suggested that surgical procedures are necessary to correct dislocations greater than 3 months despite few controversial literature suggesting that manual reduction can be possible up to 6 months [5].

There are no specific guidelines for which surgical method is best and for which condition. There are reports describing surgical treatments for long-standing dislocation of TMJ to be condylectomy, condylotomy with or without coronoidotomy, coronoidectomy alone, inverted L-shaped ramus osteotomy, modified vertical ramus osteotomy, temporalis myotomy, periosteal stripping, traction with wire to lower border, and meniscectomy [9, 10].

Lee et al. reported midline mandibulotomy for the reduction of prolonged bilateral TMJ dislocation. Mandibulotomy was

performed intra-orally and both the hemi-mandible were manipulated separately to obtain reduction. Few authors have used a closed condylotomy technique. In this technique the condylar neck was resected with a Gigli saw intra orally. The condylar head displaces in an anteromedial direction, thus eliminating the effect of the lateral pterygoid muscle spasm. Traction of the mandible by wire from the angle or zygomatic hooks placed into the sigmoid notch has also been described as a method of obtaining reduction [11]. Huang et al, suggested treatment protocol which indicated that dislocations of greater than three weeks be treated by closed reduction with or without local anaesthesia, and deep sedation or general anaesthesia if unsuccessful. For dislocations of one to three months, they suggested open reduction with stripping of periosteum and muscles and traction with wire or other retractors.

The recommendation for more than six months was open reduction and condylectomy, condylotomy, myotomy or a TMJ prosthesis. For three to six months duration, stripping is done as in the one to three month group, and if unsuccessful, following the recommendations for more than six months [5]. DENG et al. presented endoscopy-assisted reduction for a long-standing dislocation in 2007, which could be used only for dislocations of less than 4 weeks [12].

CONCLUSION:

With time dislocated condyle develops fibrous adhesions between condyle, articular disc and eminence which prevent the manual reduction and necessitating surgical reduction / correction under general anaesthesia. So it is advisable to treat such dislocations as early as possible. The treatment protocol to be used should depend on type and duration of dislocation.

REFERENCES

1. Ugboko VI, Oginni FO, Ajike SO, Olasoji HO, Adebayo ET. A survey of temporomandibular joint dislocation: aetiology, demographics, risk factors and management in 96 Nigerian cases. *Int J Oral Maxillofac Surg* 2005;34(5):499–502.
2. Bello SA, Olokun BA, Olaitan AA, Ajike SO. Aetiology and presentation of ankylosis of the temporomandibular joint: report of 23 cases from Abuja, Nigeria *Brit J Oral Maxillofacial Surgery* 2012;50:80–4.
3. Wijmenga JPH, Boering G, Blakestijn J. Protracted dislocation of the temporomandibular joint. *Int J Oral Maxillofac Surg* 1986; 5: 380–388.
4. Shorey CW, Campbell JH. Dislocation of the temporomandibular joint. *Oral Surg Oral Med Oral Pathol Oral Radiol Endod* 2000; 89: 662–668.
5. Huang IY, Chen CM, Kao YH, Chen CM, Wu CW. Management of long-standing mandibular dislocation. *Int J Oral Maxillofac Surg* 2011;40(8):810–4.
6. Debnath SC, Kotrashetti SM, Halli R, Baliga S. Bilateral vertical-oblique osteotomy of ramus (external approach) for treatment of a long-standing dislocation of the temporomandibular joint: a case report. *Oral Surg Oral Med Oral Pathol Oral Radiol Endod* 2006; 101: e79–e82.

7. Gottlieb O. Long-standing dislocation of the jaw. *J Oral Surg* 1952; 10: 28–32.
8. Mizuno A, Suzuki S, Motegi K. Articular eminectomy for long-standing luxation of the mandible. Report of 2 cases. *Int J Oral Maxillofac Surg* 1988;17(5):303–6.
9. Adekeye EO, Shamia RI, Cove P. Inverted Lshaped ramus osteotomy for prolonged bilateral dislocation of the temporomandibular joint. *Oral Surg Oral Med Oral Pathol* 1976;41(5):568–77.
10. Adekeye EO, Shamia RI, Cove P. Inverted Lshaped ramus osteotomy for prolonged bilateral dislocation of the temporomandibular joint. *Oral Surg Oral Med Oral Pathol* 1976;41(5):568–77.
11. Lee SH, Son SI, Park JH, Park IS, Nam JH. Reduction of prolonged bilateral temporomandibular joint dislocation by midline mandibulotomy. *Int J Oral Maxillofac Surg* 2006;35(11):1054–6.
12. Deng M, Dong H, Long X, Li X, Cheng Y. Endoscope-assisted reduction of longstanding condylar dislocation. *Int J Oral Maxillofac Surg* 2007; 36: 752–755.

Source of support: Nil

Conflict of interest: None declared

This work is licensed under CC BY: *Creative Commons Attribution 3.0 License*.